HUMAN FASCIOLIASIS IN RHODESIA

Report of a Case with a Liver Abscess

W. PERRY, J. M. GOLDSMID & M. GELFAND

Department of Medicine, University of Rhodesia

So far as we are aware no person showing the symptoms of fascioliasis has been reported from Rhodesia, but Goldsmid (1968) recovered eggs of *Fasciola gigantica* from the faeces of 2 Africans, although no clinical effects were described. Thornton (personal communication) refers to the instance of a member of the veterinary services who had possibly contracted the infection: when stationed at Chipinga he developed jaundice with swelling and tenderness of the liver and a distressing aversion to alcohol; before this he had been diagnosed as suffering from amoebic dysentery which was being treated with emetine. During this treatment operculate eggs of *F. gigantica* were found in his faeces.

Illustrative Case

The present patient was a thin, rather sickly looking African girl aged about 10 years, admitted to hospital on 26th June, 1970, from Marandellas with a history of 5 days' chest pain, cough and abdominal pain. Her illness appears to have started rather suddenly on waking with abdominal pain and cough. The chest pain was made worse by coughing. The cough was unproductive and gradually became less. The abdominal pain at first was not severe and was felt mainly in the right hypochondrium.

Whereas before her present illness she had had a good appetite, eating meat and stiff porridge of maize and vegetables, she had subsequently lost her desire for food and her weight had begun to fall. On the day she became ill, she had 3 bouts of loose motions. Since then she passed one bowel action a day but she noticed that the stools were very dark.

She was an intelligent and co-operative girl and said she felt feverish. The whites of her eyes were slightly but definitely jaundiced and there was a moderate pallor of the palms. No enlarged nodes were palpable in the neck, armpits and groins. At the time of her admission the abdomen was distended, there was some guarding over the right hypochondrium and, on careful palpation, a two-finger liver which was hard, nodular with an ill-defined edge, but slightly tender could be detected. The spleen was not palpable. On rectal examination the stool was of a very dark brown colour but one could not decide if it was a true melaena.

A provisional diagnosis of cirrhosis of the liver with portal hypertension and possible bleeding varices or acute infective hepatitis were considered. The patient was very mildly feverish and although the temperature often reached 99°F. it was mostly normal. The pulse also was normal.

The laboratory investigations carried out on admission indicated that the blood showed a well marked iron deficiency anaemia; haemoglobin, 6·1 g. %; PCV 21%; MCHC 29%; reticulocytes 19%; leucocytes 6,400, of which eosinophils constituted 14% (806). The total serum proteins were 6·5 g./100 ml. (albumin 2·9 g. %, globulin 3·6 g. %, A : G ratio 0·81). The bromsulphthalein retention was 8% (normal up to 5%). Bilirubin screening was negative, the alkaline phosphatase 62 K.A. units and the S.G.O.T. enzyme 35 units and S.G.P.T. 180 units. The red blood cells showed a deficiency of the G6-PD enzyme. Because of the alleged bleeding in her motions, blood clotting studies were carried out but these were normal. The urine contained 1 + urobilinogen.

On the 29th June the patient was given a blood transfusion after which her haemoglobin rose to 11·4 g. %. A rectal snip for *Schistosoma* eggs was then performed but none was found. A test for occult blood in the stool was weakly positive. No helminth eggs or amoebae were found in the stool.

At this stage we were without a confident diagnosis. We considered bleeding from eosophageal varices due to cirrhosis of the liver or from a peptic ulcer. A barium swallow and meal were carried out but no varices or peptic ulcer were discovered. By now, however, our attention was drawn to the liver. The liver itself was definitely more tender and the swelling more pronounced. Whereas the right lobe had been slightly tender it was now much more so and the swelling seemed to bring the

Reprinted from the JOURNAL OF TROPICAL MEDICINE AND HYGIENE, *November 1972, Vol. 75, pp. 221 - 223.*

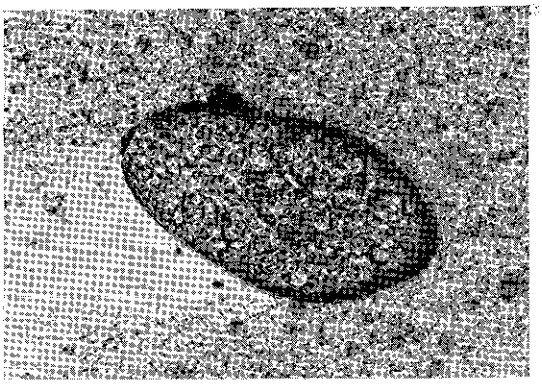

Fig. 1. Egg of *Fasciola gigantica* recovered from liver aspirate of African child. Note the small operculum at one end of the egg. (approx. x500).

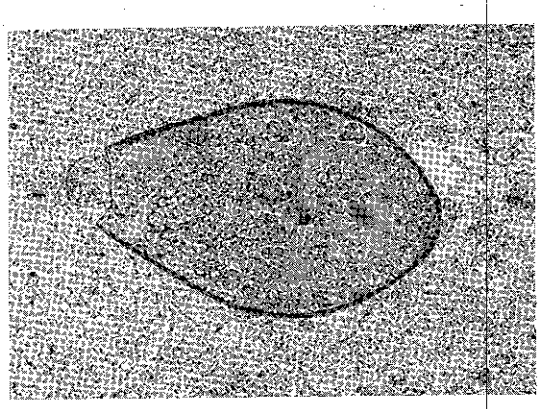

Fig. 2. Egg of *F. gigantica* recovered from liver aspirate and gently squashed to demonstrate the presence of the operculum (approx. x500).

liver down about 1 to $1\frac{1}{2}$ inches further than it did before. The child was becoming more and more distressed by this liver mass and was so tender in the right hypochondrium that we began to consider more seriously the diagnosis of an amoebic liver abscess. We had some doubt, however, as the abdominal pains seemed to be colicky in nature. We thought it safest in her interest to perform a liver biopsy and to take the specimen from the mid-axillary line rather than that from the front as we still thought cirrhosis of the liver a possibility and, if this were so, the biopsy should show changes in a disease of so diffuse a nature. This investigation was of no help. The liver cell plates were increased in size but their architecture was normal and the general tracts were not increased in size. Although this patient was a little old, the pattern was normal for a child. As her distress increased we decided to institute a course of treatment with metronidazole. She was given 1,200 mg. on the 9th and again on the 11th July. At this point we decided it best to perform a diagnostic liver aspiration. The needle was inserted in the right hypochondrium directly over the mass. On entering the mass and aspirating, the first few drops seemed to be thick, resembling anchovy pus, but it soon changed to the colour and consistency of pure blood. The first portion was submitted to the pathologist. The report was interesting. Microscopy revealed no malignant cells; there were large numbers of eosinophils, occasional protozoal-type cells (? amoebae). The amoebic latex agglutination test (Morris *et al.*, 1970) was negative but with the suspected presence of amoebic parasites, we decided to perform another aspiration. The needle was inserted close to the previous site and this time thick anchovy pus only was aspirated. The report on this specimen was: eggs of *Fasciola gigantica* present ++; Rbs's ++; Charot-Leyden crystals present ++ (Figs. 1 and 2). The eggs were typically operculate and measured 176 - 187μ × 80 - 84μ with a mean size of 180μ × 84μ, thus falling into the range of size given for *F. gigantica* by Soulsby (1968) and other authors. 6 days after starting the metronidazole, when the second aspiration was done, the patient felt much better. There was much less tenderness over the liver and the mass was now visible and clearly palpable over the outer surface of the right lobe of the liver. On the 18th July emetine hydrochloride 30 mg. i.m. daily was started. From the 19th to 20th July her condition continued to improve. The liver was still enlarged to 2 fingers with a mass still clearly to be felt on its anterior aspect. But it was much less tender than before. By the 24th July no tenderness was found over the liver and it was now enlarged to $1\frac{1}{2}$ fingers. The emetine was stopped after 11 days. By now the patient had no complaints and began to move around the ward and take an interest consistent with a girl of her age. She was discharged on the 4th August apparently cured.

Discussion

So far as we are aware this is the first record from Rhodesia of a person suffering from fascioliasis, although fascioliasis in cattle due to *F. gigantica* is widespread in this country—43% of all cattle slaughtered in Salisbury having the infection, according to Thornton as quoted by Goldsmid (1970). From a search of the published reports of the literature at our disposal, we have not discovered a record in

which the ova were found with liver aspiration although we would not be surprised to learn that this has occasionally occurred. In the recent outbreaks of the disease in England (Ashton *et al.*, 1970; Hardman *et al.*, 1970), none of the cases appeared to have been diagnosed in this way, although liver biopsies were taken in some of the investigations.

Another point of interest in this case is the fact that stool specimens were consistently negative when examined for eggs, although this has been reported for *F. hepatica* (Facey & Marsden, 1960; Ashton *et al.*, 1970; Hardman *et al.*, 1970).

A publication from Malawi (Speckhart, 1969) indicates that the disease may be common in parts of Malawi and it would not be unreasonable to assume, in view of our present finding and in the report of other possible cases, that the disease may be encountered more often, although it does not appear to be prevalent in Rhodesia. However, Speckhart reports the cases in Malawi as being caused by *F. hepatica*—a fluke more frequently recorded from man than *F. gigantica* (Watson, 1960; Belding, 1965) and serious outbreaks of fascioliasis due to *F. hepatica* have recently been reported from Monmouthshire and Shropshire in England (Hardman *et al.*, 1970; Ashton *et al.*, 1970).

Liver disease is one of the main disorders in Rhodesia and although much of it is due to a variety of causes it is possible that human fascioliasis is more common than was hitherto believed, but one must exercise caution in making the diagnosis on patients passing eggs of *Fasciola* owing to "transit eggs" being passed in cases of spurious parasitism (Goldsmid, 1970). It may be confused readily with amoebic hepatitis in view of the tender and swollen liver. It may also be mistaken for acute infective hepatitis and even for the more chronic disorders of cirrhosis or primary carcinoma of the liver. Perhaps the safest way is always to have this infection in mind when confronted with a hepatic disorder.

Summary

A Rhodesian African developed an abscess of the liver due to *Fasciola gigantica*.

Eggs of this species and also many pus cells were recovered from the aspirate from the liver. We have been unable to find a record of a similar case in which the eggs were aspirated from the liver.

The patient made a very good recovery with metronidazole and emetine treatment.

References

Ashton, W. L. G., Boardman, P. L., D'Sa, C. J., Everall, P. H. & Houghton, A. W. J., 1970.
Human fascioliasis in Shropshire. *Br. med. J., v3,* 500 - 502.

Belding, D. L., 1965.
Textbook of parasitology. 3rd Ed. *New York: Appleton - Century - Crofts,* pp. 665 - 671.

Facey, R. V. & Marsden, P. D., 1960.
Fascioliasis in man: an outbreak in Hampshire. *Br. med. J., v2,* 619 - 625.

Goldsmid, J. M., 1968.
Studies on intestinal helminths in African patients at Harari Central Hospital, Rhodesia. *Trans. R. Soc. trop. Med. Hyg., v62,* 619 - 629.

Goldsmid, J. M., 1970.
Spurious parasites recovered from stools and urines in Rhodesia. *Cent. Afr. J. Med., v16,* 173 - 178.

Hardman, E. W., Jones, R. L. H. & Davies, A. H., 1970.
Fascioliasis—a large outbreak. *Br. med. J., v3,* 502 - 505.

Morris, M. N., Powell, S. J. & Elsdon-Dew, R., 1970.
A rapid latex-agglutination test for invasive amoebiasis. *S. Afr. med. J., v44,* 594 - 595.

Soulsby, E. J. L., 1968.
Textbook of Veterinary Clinical Parasitology. Vol. 1. Helminths. *Oxford: Blackwell,* pp. 531 - 581.

Speckhart, V. J., 1969.
Human fascioliasis in Malawi. *Malawi Med. Bull., v3,* 1 - 6.

Watson, J. M., 1960.
Medical Helminthology. *London: Baillière, Tindall & Cox,* pp. 244 - 248; 257.